

PATIENT

Lola Stewart

SPECIES

Canine

BREED

Boston terrier

SEX

FS

AGE

3 years

WEIGHT

7.9 kg

INTERPRETED BY

Remo Lobetti, BVSc,
MMedVet (Med),
PhD, Dipl. ECVIM

**IMAGING
PERFORMED BY**

Dr Donna Markland,
DVM

HOSPITAL NAME

Prevost Veterinary
Clinic

REFERRING VET

INVOICE

302758

DATE

2/17/22

PRESENTING CLINICAL SIGNS

History: Six-week duration of abdominal pain and vomiting, with good response to famotidine and Cerenia but relapses as soon as drugs are withdrawn. On GI food.

Physical Examination: BCS 5/9.

Urinalysis: N/A.

CBC: Pending.

Serum Biochemistry: Mild hypoproteinemia with albumin and globulin within reference range. Elevated TLI. Normal folate, cobalamin, and cPL.

Radiographic Findings: N/A.

ULTRASONOGRAPHIC EXAMINATION OF THE ABDOMEN

Urinary System

Full urinary bladder with a normal appearance and thickness of the wall. Normal anechoic urine with no sediment or uroliths evident.

Normal trigone area, proximal urethra, and iliac blood vessels.

Normal iliac lymph nodes. Ureters not visualized.

Normal renal size (both 3.9 cm), echogenic appearance, cortico-medullary differentiation, blood flow, capsule and pelvis.

Reproductive System

N/A.

Adrenal Glands

Normal shape, echogenic appearance, size, and position. Left 1.46 x 0.38 cm, right 1.94 x 0.64 cm.

Spleen

Normal size and echogenic appearance. Smooth homogenous parenchyma, smooth curvilinear capsule, and normal vasculature. No evidence of inflammatory, neoplastic, infarction, or infiltrative changes noted.

Liver

Normal size, echogenic appearance, and portal markings. No nodules or masses evident. Full gall bladder containing normal anechoic bile. Normal thickness and appearance of the gall bladder wall. Normal bile duct.



PATIENT

Lola Stewart

SPECIES

Canine

BREED

Boston terrier

SEX

FS

AGE

3 years

WEIGHT

7.9 kg

INTERPRETED BY

Remo Lobetti, BVSc,
MMedVet (Med),
PhD, Dipl. ECVIM

**IMAGING
PERFORMED BY**

Dr Donna Markland,
DVM

HOSPITAL NAME

Prevost Veterinary
Clinic

REFERRING VET

INVOICE

302758

DATE

2/17/22

Gastrointestinal

Normal appearance of the stomach, small intestine, and colon with no loss of layering, normal wall thickness and peristalsis, and no distension of the lumen. Normal thickness of the duodenum (0.5 cm) with a prominent hypoechoic appearance of the submucosal layer and patchy mucosal stippling. Enlarged and irregular ileo-cecal junction (5.9 cm) with a mottled echogenic appearance, loss of layering, small amount of fluid accumulation around it, and an onion skin appearance on some of the views. Visible ileo-cecal lymph node (0.6 cm) with normal size, shape and echogenic appearance.

Pancreas

Normal size and echogenic appearance. Regular capsule. Normal echogenic appearance of the mesentery and fat surrounding the pancreas.

Free Abdomen

No mesenteric lymphadenomegaly.
No ascites.

ULTRASONOGRAPHIC FINDINGS

Primary findings:

- Ileo-cecal pathology.
- Duodenitis.

Secondary findings:

- None.

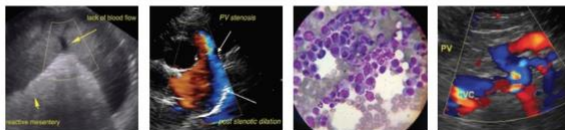
INTERPRETATION OF THE FINDINGS & FURTHER RECOMMENDATIONS

Etiologies for the ileo-cecal pathology would be intussusception, granulomatous reaction, focal perforation, and neoplasia.

Etiologies for the duodenitis would be non-specific (viral, bacterial, helminths, protozoal, dietary indiscretion), inflammatory bowel disease, lymphangectasia, and dietary hypersensitivity.

Further assessment would be 3-view thoracic radiographs and fecal analysis. FNA cytology of ileo-cecum can be considered, however, a laparotomy would be indicated as it could be both diagnostic and therapeutic as well as allowing obtaining full thickness biopsies of the duodenum.

Specific therapy would be dependent on an etiological diagnosis.



PATIENT

Lola Stewart

SPECIES

Canine

BREED

Boston terrier

SEX

FS

AGE

3 years

WEIGHT

7.9 kg

INTERPRETED BY

Remo Lobetti, BVSc,
 MMedVet (Med),
 PhD, Dipl. ECVIM

IMAGING PERFORMED BY

Dr Donna Markland,
 DVM

HOSPITAL NAME

Prevost Veterinary
 Clinic

REFERRING VET

INVOICE

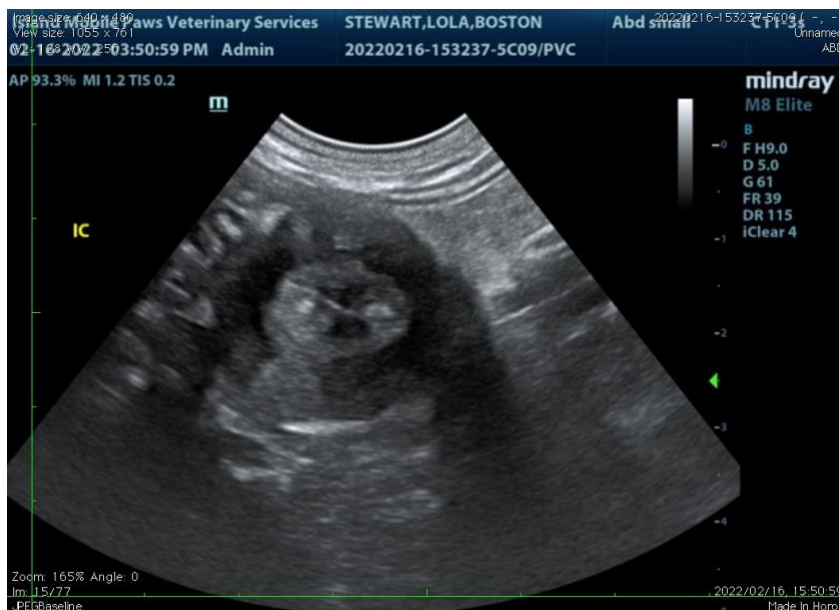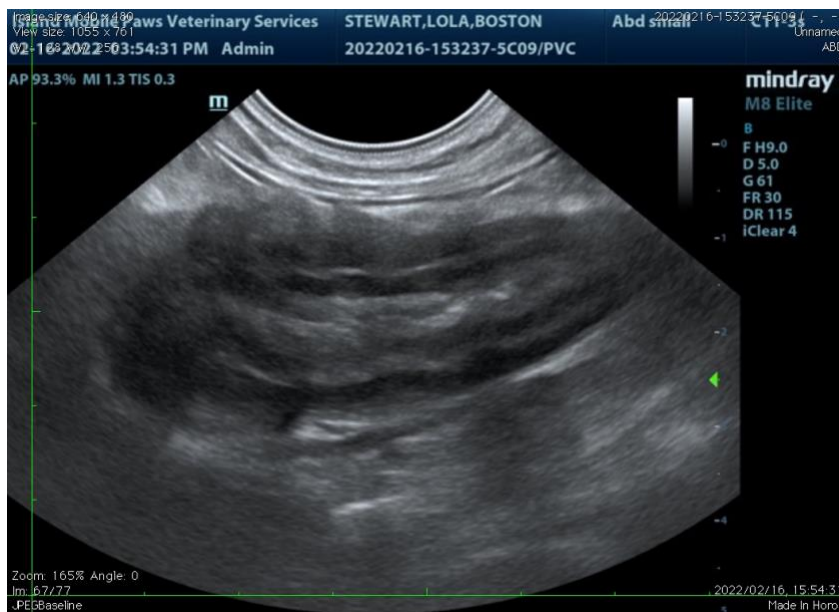302758

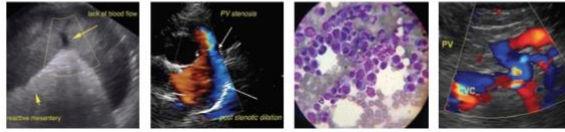
DATE

2/17/22

IMAGES

Ileo-cecal junction





PATIENT

Lola Stewart

SPECIES

Canine

BREED

Boston terrier

SEX

FS

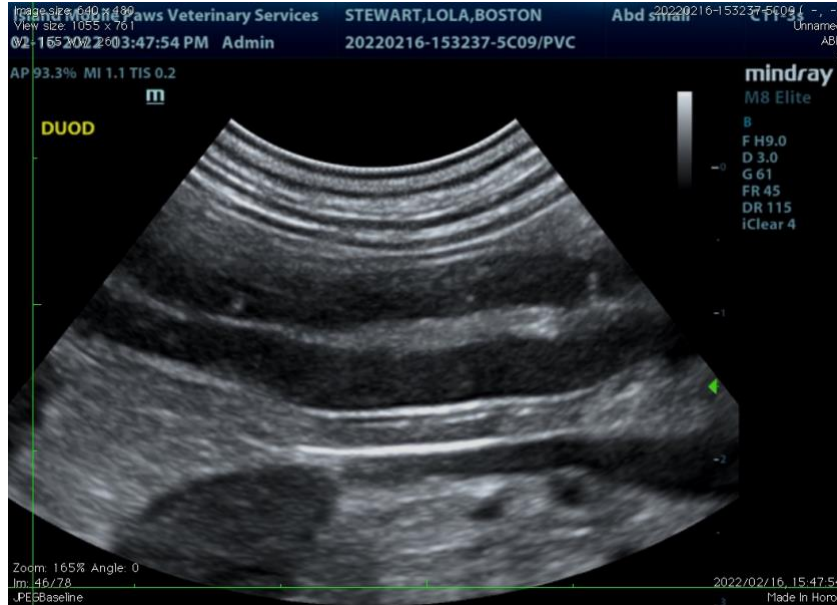AGE

3 years

WEIGHT

7.9 kg

Duodenum



INTERPRETED BY

Remo Lobetti, BVSc,
MMedVet (Med),
PhD, Dipl. ECVIM

IMAGING PERFORMED BY

Dr Donna Markland,
DVM

HOSPITAL NAME

Prevost Veterinary
Clinic

REFERRING VET

INVOICE

302758

DATE

2/17/22

The information and recommendations provided are based on the images presented by the referring veterinarian. No evaluation can be communicated regarding pathology that was not visible in the image/video clips provided.

Thank you for this referral. If the clinical or image interpretation does not parallel your findings or if I can be of any further assistance please contact me.

Remo Lobetti, BVSc, MMedVet (Med), PhD, Dipl. ECVIM (Internal Medicine)
rlobetti@mweb.co.za